

# Balloon tamponade for prevention and treatment of vaginal hemorrhages in gynecology

G. Ghirardini, C. Alboni

*Obstetrics and Gynecology Unit, New Civil Hospital, Sassuolo (MO) (Italy)*

## Summary

The preliminary experience of balloon tamponade in planned vaginal surgery and in emergency vaginal bleeding using a new device (Vagistop) is reported. The results shows the advantages of the system in comparison with vaginal gauze packing.

*Key words:* Vaginal surgery; Vaginal balloon tamponade; Vagistop.

## Introduction

Vaginal packing with gauze is commonly used in vaginal surgery for different conditions. This type of tamponade is performed with the aim to stop venous bleeding of the dissected vaginal tissue and to avoid subsequent bleeding and haematomas formation. In most cases, the tamponade is removed after 24 hours [1-3].

However, the long gauze used for this procedure may absorb blood and conceal considerable blood loss. Moreover retaining and removal of vaginal gauze is not comfortable for the patient.

The authors describe their experience with balloon tamponade after vaginal surgery in 85 consecutive cases using a new tamponade system, Vagistop, a balloon specifically created for vaginal distension and inspection (Figure 1). This preliminary experience has encouraged the authors to use Vagistop for severe vaginal obstetric haemorrhages [4].

## Materials and Methods

Vaginal balloon tamponade with Vagistop was used at the end of vaginal surgery in 80 consecutive cases of planned vaginal surgery and in five cases of emergency vaginal surgery (Table 1), from January 2011 to June 2012. The 80 planned cases underwent vaginal surgery for prolapse, in most cases with associated hysterectomy.

At the end of surgical procedure, Vagistop was applied. The device is made of a flexible tube with a balloon tip, connected to a syringe through a valve that allows inflating the balloon continuously, without pulling out the syringe. The balloon is inserted until the posterior vaginal fornix or cuff. After insertion the balloon is inflated with air using a 20-ml syringe connected to the inflation tube through the valve (Figure 1) until the whole vaginal space is occupied (Figure 2); at this point the balloon internal pressure is about 50 mmHg, greater than the venous pressure in the pelvis. The material of the surface of the balloon is a polymer that allows the device to adhere to the vaginal walls. The total capacity of the balloon is 250 ml. The air volume used ranged from 180 to 40 ml, with an average of 90 ml.

Table 1. — *Cases with emergency vaginal balloon tamponade.*

Case no.	Type of problem	Volume used	Time in place (hours)	Result
1	Laparotomy for retroperitoneal mass	180	24	good
2	Bleeding after Bartholin's cyst removal	140	24	good
3	Bleeding after vaginal cyst removal	140	24	good
4	Hemorrhage 3 days after vaginal cyst removal	140	24	good
5	Hemorrhage 2 days after conization	140	24	good

## Results

The balloon was deflated and removed 24 hours later. In ten cases Vagistop was expelled spontaneously between two and six hours after surgery. Expulsion occurred in all cases with severe postoperative vomiting.

In all cases the nurse easily removed Vagistop. None of the patients complained of discomfort (VAS score 0/10). No bleeding occurred in any of the cases.

## Discussion

Vaginal tamponade with gauze is a commonly used procedure at the end of different vaginal surgical procedures [1-3]. The aim is to avoid bleeding and haematomas caused by venous bleeding of the dissected vaginal tissue. Gauze packing is however a matter of discomfort for the woman and may absorb a lot of blood before evidence of persisting bleeding is recognized.

As far as the authors know, only one case of balloon tamponade for vaginal hemorrhage in gynecology has been published [5]. The authors' previous positive experience in obstetrics with vaginal balloon tamponade with Vagistop [4] led them to apply Vagistop in substitution of gauze packing in vaginal surgery. Simple and rapid application and removal, both in planned and in emergency surgeries (without use of anaesthesia), compliance of the patients, as well as optimal adhesion to vaginal walls, are the main advantages of Vagistop in comparison with gauze packing.

Revised manuscript accepted for publication December 27, 2012

Fig. 1

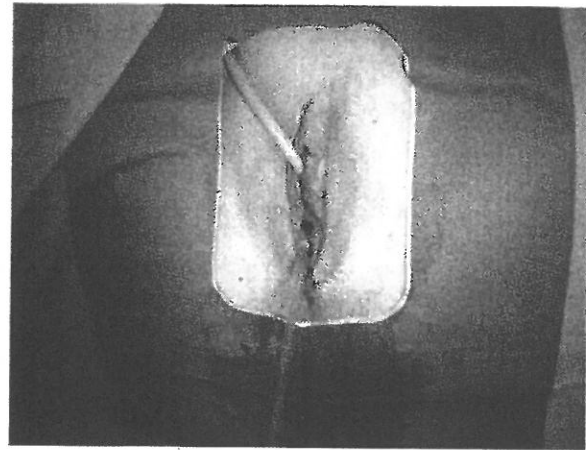
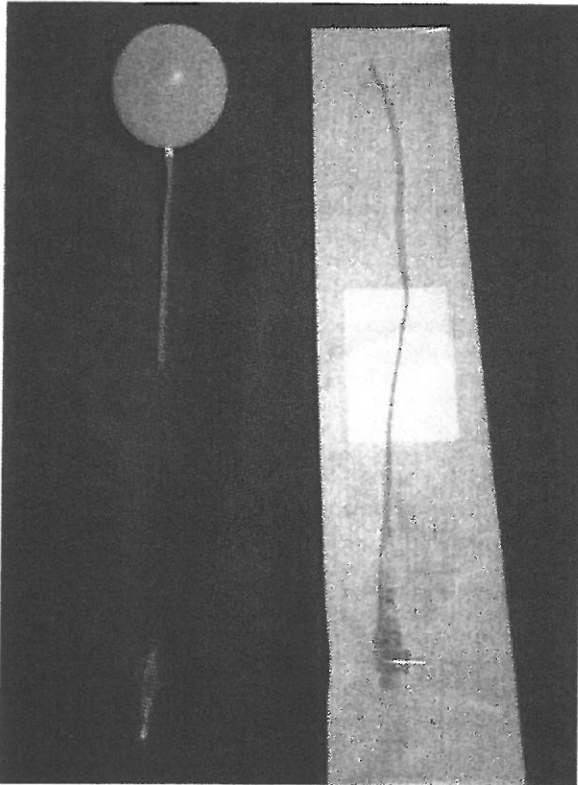


Fig. 2

Figure 1. — Vagistop.

Figure 2. — Vagistop after application.

### Conclusions

The results obtained in this preliminary case justify the use of vaginal balloon tamponade to prevent and treat vaginal bleeding and haematomas in vaginal surgery, as well as in an emergency setting.

### References

- [1] Rock J.A., Jones H.W. III (eds.): *Te Linde's operative gynecology*, 10th ed., Philadelphia, Lippincott, 2008.
- [2] Reiffenstuhl G., Platzer W., Knapstein P.: "Die vaginalen Operationen: chirurgische Anatomie und Operationslehre". Urban Schwarzenberg, München, 1994.
- [3] Webb M.J. (ed.): *Mayo Clinic Manual of Pelvic Surgery*, 2nd ed. Philadelphia, Lippincott, 2000.

- [4] Ghirardini G., Alboni C., Mabrouk M.: "Use of balloon tamponade in management severe postpartum hemorrhage and vaginal hematoma: a case series". *Gynecol. Obstet. Invest.*, 2012, 74, 320. doi: 10.1159/000339931. Epub 2012 Aug 16.
- [5] Schlicher N.R.: "Balloon compression as treatment for refractory vaginal hemorrhage". *Ann. Emerg. Med.*, 2008, 52, 148.

Address reprint requests to:

G. GHIRARDINI, M.D.  
 New Civil Hospital  
 Via Ruini 2, I  
 41047 Sassuolo, MO (Italy)  
 e-mail: g.ghirardini@ospedalesassuolo.it